

# Incidentally detected peritoneal Mesothelioma in An Inguinalhernia Sacafter An Urgentoperation: Report of A Case

Ilhan B\*

Department of General Surgery, Istanbul Faculty of Medicine, Istanbul University, Millet Caddesi, 34093 Fatih, Istanbul, Turkey

Volume 1 Issue 5- 2018

Received Date: 15 Sep 2018

Accepted Date: 18 Oct 2018

Published Date: 24 Oct 2018

## 1. Abstract

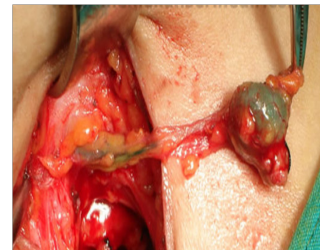### Purpose

Malignmesotelioma can be causedbyserozalleaves of pleura, pericard, peritoneum, tunicavaginalisor testis. Inthe United States, about 2500 newcases of mesothelioma are reported each year. Most frequent type is pleural mesothelioma, second frequent type is peritoneal mesothelioma. The annual incidence of malignant peritoneal mesothelioma is one in about 1,000,000 people.

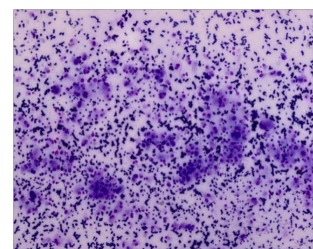
Intheetiologi of malignant mesothelioma, prevalence of as best osex posure, as well as othere nviro nmental agents, radiation, chronic pleural and peritoneal inflammation and irritation, viralagents can be thecause. Malignmeso the liomadetection in theinguinalhernia sac islimit-edonly in casereports in theliterature. Theaim of thisstudy is topresent a patient, whoneededur-gentoperationbecause of an etrangulatedinguinalherniaanda casewithmalignmesotelioma in hernia sac.

## 2. Case Presentation

A55 yeras old patient with no know ncommon disease and no family history admitted to emergency clinic with complaints of painful swelling in ther ightinguinal region. There was a work-ing history in the dyefactory. When the etrangule right ingui-nal hernia findings were detected on the physicaalexamination of the right inguinal region an emergency operation decision was made for the patient [1-4]. During surgery, massive degenera-tive elastic mass lesions were detected in the right inguinal her-nia sac and in dimensions of approximately 3x2 cm (**Figure 1**). Mass excision was performed and the inguinal hernia was re-paired with prolen graft.The pathologic ezamination result was epitheloid type malignant mesothelioma (**Figure 2**). The patient was consulted to medical oncology section and pemetrexed and cisplatin treatment started to the patient. At the 6th month computed tomography (CT) revealed a few hypodense nodular lesions in the liver, splenic flexure, mild wall thickening in the transverse colon, and free fluid between the intestins. No further pathology was detected except Positron eemission tomography / CT except mild hypermetabolic nodular lesions in thelung (nod-uleswithSUDmax: 3.70, 12 mm in size). The patient was diverted to medical oncology for further continued therapy of palliative chemotherapy.



**Figure 1:** Multicycliclesion in hernia sac.



**Figure 2:** Peritonealmesothelioma (HEX20).

## 3. Discussion

Most mesothelioma soccur in the pleural or peritoneal space. Mesotheliomas, which are arising from cell slining hernia sutures are very rare [5]. It has been reported that only%7 of all peritoneal mesothe liomasaccompany inguinal and umbilical hernia [6]. The absence of specific findings makes it difficult toi-identify in a pre-operative process. Most of these tumors are de-tecting during surgery [7].

\*Corresponding Author (s): Burak Ilhan, Department of General Surgery, Istanbul Faculty of Medicine, Istanbul University, Millet Caddesi, 34093 Fatih, Istanbul, Turkey; E-mail: burakmd@yahoo.com

The presence of abdominal pain and ascites with a rapidly growing hard lesion in the hernia sac should make the surgeon suspect the possibility of the tumor. Preoperative ultrasonography can help by showing non-homogeneous effusion or exophytic tumor for more information. It should be kept in mind that liquid cytology may also be descriptive. If there is a suspicion for a tumor, histologic frozen section examination must be performed [7]. It is necessary to distinguish the primary mesothelioma of the hernia sac from the diffuse peritoneal malignant mesothelioma and metastatic carcinomas. Appropriate radiological, surgical, and pathologic identification techniques differential diagnosis (Figure 1). It has been reported that mesotheliomas with minimal peritoneal spread localized within the hernia sac have a better prognosis than diffuse peritoneal or pleural mesotheliomas (Figure 2) [7]. It is emphasized that asbestos exposure plays an important role in both pleural and peritoneal mesothelioma. Peritoneal mesothelioma associated with asbestos exposure is more common in males than in females [8]. Mesothelioma has also been observed in patients who have been exposed to radiation due to over cervical cancer or as the cause [9]. Contrast agents such as thorotrast and some viral agents such as SV40 have also been reported to cause peritoneal mesothelioma formation [10,11]. Peritoneal and inguinal canal mesothelioma cases due to familial Mediterranean fever and recurrent diverticulitis due to prolonged peritoneal irritation and inflammation have been reported in the literature [12-14].

Malignant peritoneal mesothelioma is an aggressive tumor with poor prognosis. The effects of aggressive surgery, abdominal radiotherapy and systemic chemotherapy, which we can use in the treatment of malignant peritoneal mesothelioma, are limited to this disease. The effectiveness of the treatment options depends on the age of the patient, overall performance, and histology of the tumor [15,16]. In the literature, that systemic chemotherapy combined with surgical debulking affects the patient's survival positively, was reported. It was also emphasized that debulking is an effective combination of intra abdominal chemotherapy in patients with minimized tumor volume. However, the specified treatment combinations have not been standardized [17,18].

#### 4. Conclusion

Malignant mesothelioma is a rare malignant disease that is difficult to diagnose and treat. One of the most rare anatomic regions of the mesothelioma is the inguinal canal. It is possible to suspect the inguinal canal mesothelioma based on patient history, clinical findings, and rigorous radiological examination (such as ultrasonography, computerized tomography). However, inguinal canal mesotheliomas are usually detected during the incisional / extracanal inguinal hernia diagnosis and definitive diagnosis is the

result of pathologic examination. Combination of systemic chemotherapy and radiotherapy given by debulking aimed at reducing the tumor burden in malignant mesotheliomas and considering the age and performance of the patient and the pathology result may contribute to the survival time of the patient.

#### Reference

1. Hasan R, Alexander R. Nonpleural mesotheliomas: mesothelioma of the peritoneum, tunica vaginalis, and pericardium. *Hematol Oncol Clin North Am.* 2005; 1067-1087.
2. Mohammed F, Sugarbaker PH. Peritoneal mesothelioma. *Curr Treat Options Oncol.* 2002; 3: 375-386.
3. Price A, Ware M. Mesothelioma trends in the United States: an update based on surveillance, epidemiology, and end results program data from 1973 through 2003. *Am J Epidemiol.* 2004 Jan 15; 159(2): 107-12.
4. Vogelzang NJ. Emerging insights into the biology and therapy of malignant mesothelioma. *Semin Oncol* 2002; 29: 35- 42.
5. Battifora H, McCaughey WTE. Tumors and pseudotumors of the serosal membranes. In: Atlas of tumor pathology, 3rd series, fascicle 15. Washington, DC: Armed Forces Institute of Pathology. 1995; 15-88.
6. Mirabella F. Peritoneal mesothelioma and abdominal hernias. *Minerva Med.* 1996; 87: 21-4.
7. Testini M, Scattone A, DiVenere B. Primary malignant peritoneal mesothelioma in an incarcerated groin hernia: report of a case. *Surg Today.* 2005; 35: 421-424.
8. R Spirtas, E F Heineman, L Bernstein. Malignant mesothelioma: *Occup Environ Med.* 1994; 51(12): 804-11.
9. Amin A, C Mason, P. Rowe Diffuse malignant mesothelioma of the peritoneum following abdominal radiotherapy. *Eur J Surg Oncol.* 2001; 214-215.
10. R Maurer, B. Egloff Malignant peritoneal mesothelioma after cholangiography with thorotrast *Cancer.* 1975; 1381-1385.
11. K V Shah Causality of mesothelioma: SV40 question *Thorac Surg Clin.* 2004; 497-504.
12. Chahinian AP, Pajak TF, Holland JF, Norton L, Ambinder RM, Mandel EM. Diffuse malignant mesothelioma. Prospective evaluation of 69 patients. *Ann Intern Med* 1982; 96: 746-55.
13. Gentiloni N, Febbraro S, Barone C, Lemmo G, Neri G, Zannoni G, et al. Peritoneal mesothelioma in recurrent familial peritonitis. *J Clin Gastroenterol* 1997; 24: 276-9.
14. Riddell RH, Goodman MJ, Moossa AR. Peritoneal malignant mesothelioma in a patient with recurrent peritonitis. *Cancer* 1981; 48: 134-9.

15. Tani M, Tanimura H, Yamaue H, Mizobata S, Yamamoto M, Iwahashi M, et al. Successful immuno chemotherapy for patients with malignant-mesothelioma: report of twocases. *SurgToday*. 1998; 28: 647-51.
16. Sridhar KS, Doria R, Raub WA, Thurer RJ, Saldana M. New strategiesare needed in diffuse malignant mesothelioma. *Cancer*. 1992; 70: 2969-79.
17. Schmidt SC, Weidemann H, Muller KM, Krismann M, Langrehr JM, Neuhaus P. Lowmalignant epithelioid peritoneal mesothelioma: successful treatment with surgical therapyalone. *Hepato Gastroenterology*. 2002; 49: 366 -70.
18. Markman M, Kelsen D. Efficacy of cisplatin-based intraperitoneal mesothelioma. *J CancerClinOncol*. 1992; 118: 547-50.