

# Effects of an Alkalinization Therapy on Nivolumab in Esophago-gastric Junction Adenocarcinoma: A Case Report

Hamaguchi R<sup>1\*</sup>, Narui R<sup>1</sup>, and Wada H<sup>1,2</sup>

<sup>1</sup>Department of Oncology, Japanese Society on Inflammation and Metabolism in Cancer, Kyoto, Japan

<sup>2</sup>Department of Oncology, Professor Emeritus, University of Kyoto, Karasuma Wada Clinic

Volume 2 Issue 1- 2019

Received Date: 04 Apr 2019

Accepted Date: 24 Apr 2019

Published Date: 02 May 2019

## 2. Keywords

Alkalinization therapy; Esophagogastric junction adenocarcinoma; Tumor microenvironment; Sodium bicarbonate; Alkaline diet; Urine pH

## 1. Abstract

Nivolumab, a fully human IgG4 monoclonal antibody inhibitor of Programmed Death-1 (PD-1) was suggested to provide potential survival benefit in patients with advanced, chemotherapy-refractory Esophago Gastric Junction (EGJ) adenocarcinoma. An acidic tumor microenvironment is reported to be associated with suppression of cancer immunity and it is reported that the alkalinization effect of bicarbonate enhanced the effect of anti-PD-1 therapy in mouse models of melanoma. In this case study, we reported an EGJ adenocarcinoma case treated with combination therapy of nivolumab and an alkalinization therapy consisting of an alkaline diet and bicarbonate. A 76-year-old man was given a diagnosis of EGJ adenocarcinoma, HER2 negative, clinical stage IV (cT3N1M1). Nivolumab as fourth-line treatment after S-1 plus oxaliplatin, irinotecan and nab-paclitaxel, was started at 9 months from diagnosis. Alkalinization therapy containing alkaline diet (more fruits and vegetables and no meat or dairy products) and oral sodium bicarbonate (1.5 g/day) intended to alkalinize the acidic tumor microenvironment was given with nivolumab. His median urine pH level was higher than 7.0 after initiation of alkalinization therapy, although human urine pH levels depend on daily diet and are usually from 5.0 to 6.0. His tumor marker carbohydrate antigen 19-9 which had been extremely high (2,584,107 U/ml) decreased to the normal range after nivolumab therapy. His CT scan at 12 months after nivolumab therapy showed good partial response. Our case report may be the first to describe that the combination of nivolumab with alkalinization therapy showed an encouraging response in an advanced EGJ adenocarcinoma patient.

## 3. Introduction

Esophagogastric junction (EGJ) adenocarcinoma is relatively rare in Japan and standardization of treatment has not been established. A retrospective study that analyzed patients with inoperable advanced or recurrent gastric and EGJ adenocarcinoma who had received chemotherapy, reported that results of chemotherapeutic strategies did not differ between gastric and EGJ adenocarcinoma, and that treatment outcomes were equivalent [1]. Therefore, it appears reasonable that systemic chemotherapy based on gastric cancer can be applied to EGJ adenocarcinoma. In advanced or recurrent gastric cancer, S-1 with cisplatin therapy or S-1 with oxaliplatin therapy is performed as the first-line chemotherapy for HER2-negative gastric cancer [2,3]. For HER2-positive gastric cancer, trastuzumab therapy is added [4].

Docetaxel or paclitaxel, irinotecan (CPT-11) is used as second-line treatment [5-7]. A prospective phase III trial showed that ramucirumab, a monoclonal antibody VEGFR-2 antagonist, in combination with paclitaxel significantly increased overall survival (OS) in advanced gastric cancer compared with placebo with paclitaxel as second-line treatment [8]. Moreover, a randomized phase III trial suggested nivolumab, a fully human IgG4 monoclonal antibody inhibitor of programmed death-1 (PD-1), had a survival benefit in Asian patients with advanced gastric or EGJ cancer who had previously been treated with two or more chemotherapy regimens, compared with placebo [9].

Cancer cells have a tendency to generate adenosine triphosphate (ATP) via aerobic glycolysis even in the presence of sufficient oxygen, while normal cells usually produce ATP via oxidative

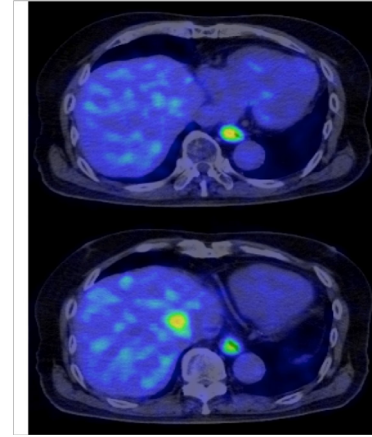
\*Corresponding Author (s): Reo Hamaguchi, Department of Oncology, Japanese Society on Inflammation and Metabolism in Cancer, 119 Nishioshikouji-cho, Higashinotouin-nishiiru, Oshikouji-street, Nakagyo-ku, Kyoto 604-0842, Japan, E-mail: reo-h@nifty.com

phosphorylation [10,11]. The acidic tumor microenvironment due to activated glycolysis is reported to be associated both with the progression and drug resistance of solid tumors [12,13]. It has been demonstrated that sodium bicarbonate administration can increase the pH of the external tumor microenvironment and that alkalization of tumor acidity is associated with the antitumor effects in several *in vivo* and *in vitro* studies [14]. In healthy volunteers, a prospective clinical trial confirmed that the long-term administration of sodium bicarbonate (0.5 g/kg/day) was feasible and safe [15]. In mouse models of melanoma, alkalization effect of bicarbonate was demonstrated to enhance the effect of anti-PD-1 therapy [16]. Moreover, our group reported that an alkaline diet (eating fruit and vegetables and limiting meat and milk) associated with alkalization of urine pH ( $6.95 \pm 0.05$ ), and prolonged progression-free survival (19.5 months) was observed in advanced lung cancer patients (n = 11) with epidermal growth factor receptor-tyrosine kinase inhibitor (EGFR-TKI) [17]. In this case study, we reported an EGJ adenocarcinoma case treated with nivolumab combined with an alkalization therapy which contains an alkaline diet and supplementary bicarbonate administration.

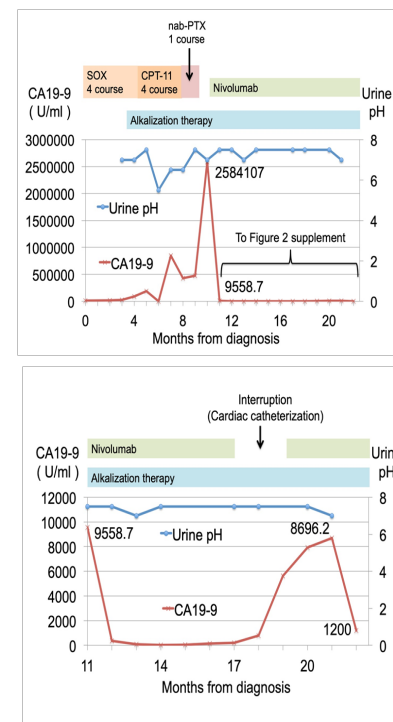
#### 4. Case Report

A 76-year-old man had been followed for Stanford type B aortic dissection since 2 years previously. A follow-up chest and abdominal computed tomography (CT) examination revealed marginally unclear low density areas in the liver. Therefore, a positron emission tomography (PET)/CT examination was done and it found abdominal  $^{18}\text{F}$ -fluorodeoxy glucose accumulation at the EGJ and liver (**Figure 1**). Subsequently, a protruding lesion was found in the EGJ during an upper gastrointestinal tract endoscopic examination, and a biopsy was performed. Pathological examination showed adenocarcinoma and he was given a diagnosis of EGJ adenocarcinoma, HER2 negative, clinical stage IV (cT3N1M1). Chemotherapeutic strategies and trends of data are shown in **Figure 2**. S-1 (120 mg/day) for 2 weeks with oxaliplatin (170 mg/body) on day 1, every 3 weeks, as first-line treatment was started. He had fatigue of grade 2 in accordance with the Common Terminology Criteria for Adverse Events (CTCAE) version 4.0 and the dose of S-1 was reduced to 100 mg/day from the second course. Alkalization therapy intended to alkalinize the acidic tumor microenvironment was started with chemotherapy at 3 months from diagnosis. Alkalization therapy was defined as treatment to have an alkaline effect, consisting of an alkaline diet and supplementary bicarbonate. The patient was instructed to take at least 400 g of fruits and vegetables per day and not to take meat and dairy products and oral bicarbonate (1.5 g once daily before going to bed) was given. After completion of 4 courses of S-1 plus oxaliplatin (SOX) treatment, his CT scan showed progressive disease (PD). Then CPT-11 (200 mg/body) as second-line treatment

was started. After completion of 4 courses of CPT-11, his CT scan showed PD again (**Figure 3a**). Although nab-paclitaxel as third-line treatment was started, it was terminated after just 1 course owing to peripheral motor/sensor neuropathy of grade 3, in accordance with CTCAE v4.0. Finally, nivolumab (3 mg/kg), every 2 weeks as fourth-line treatment was started at 9 months from diagnosis.



**Figure 1:** PET/CT scan at diagnosis. Abdominal  $^{18}\text{F}$ -fluorodeoxy glucose accumulation in the EGJ and liver are shown.

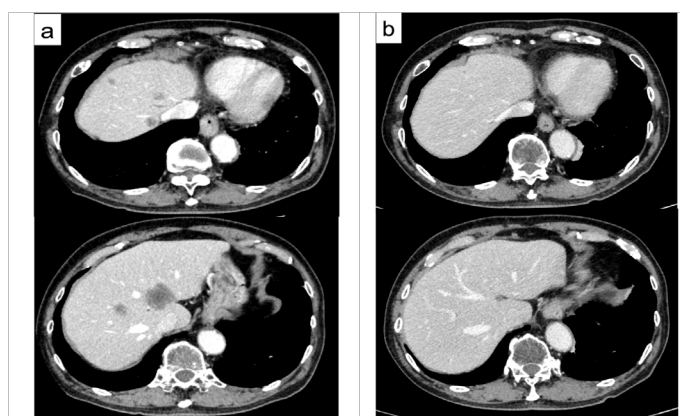


**Figure 2:** Clinical course of the patient. SOX, S-1 plus Oxaliplatin; CPT-11, irinotecan; nab-PTX, nab-paclitaxel.

Urine pH was analyzed on regular visits approximately once per month after the start of an alkalization therapy. His median urine pH level was 7.25 and was higher than 7.0 after alkalization therapy. Although human urine pH levels depend on daily diet, they are usually from 5.0 to 6.0. His tumor marker carbohydrate antigen 19-9 (CA19-9) which had been extremely high (2,584,107 U/ml) decreased to the normal range after nivolumab therapy (**Figure 2**). Nivolumab treatment was temporally interrupted during 2 months (at 17 to 19 months from diagnosis), because cardiac

catheterization was conducted due to a heart attack. Although his CA19-9 was elevated (8,696.2 U/ml) during interruption of nivolumab treatment, it decreased again after resumption. His CT scan at 12 months (21 months from diagnosis) after nivolumab-with alkalization therapy showed that the primary lesion and the liver metastases had shrunk (**Figure 3b**), however drug-induced pneumonia due to nivolumab was suspected and his nivolumab treatment was stopped.

This case study was approved by the Institutional Review Board of the Japan-Multinational Trial Organization. Written informed consent was obtained from the patient for publication of this case report and accompanying images.



**Figure 3:** (a) Contrast enhanced CT scan before start of nivolumab; Swelling of the EGJ and low density areas in the liver are shown. (b) Contrast enhanced CT scan at 12 months (21 months form diagnosis) after nivolumab initiation; Shrinkage of the EGJ tumor and liver metastases are shown.

## 5. Discussion

In this case, we reported on the treatment progress of fourth-line treatment of nivolumab in EGJ adenocarcinoma patient with an alkalization therapy intended to alkalize the tumor microenvironment. After nivolumab therapy, his tumor marker CA19-9 level (2,584,107 U/ml) decreased remarkably to within the normal range. In a phase III trial, patients in the nivolumab group with advanced gastric or gastric–esophageal junction cancer refractory to, or who were intolerant of, two or more previous regimens of chemotherapy had better median OS compared with a placebo group (5.26 months [95% CI 4.60-6.37] vs. 4.14 months [3.42-4.86]) [9]. Our case showed stable disease at 12 months after initiation of nivolumab therapy with alkalization therapy.

Daily diet is known to have an effect to pH in human body. It is reported that renal net acid excretion predicted the acid–base balance and that fruits and vegetables have an alkaline effect on urine pH, while meat and dairy products have an acidic effect on urine pH [18]. Our previous study of lung cancer patients showed a significant elevation of urine pH after start of an alkaline diet which contains with more fruits and vegetables and less meat and dairy products (n = 11) [17]. Bicarbonate is also known to have an alkaline effect. A prospective human clinical

trial showed that the long-term administration of sodium bicarbonate (0.5 g/kg/day) was feasible and safe, and bicarbonate consumption was associated with urine pH elevation [15]. Computer simulation studies and mathematical models confirmed that bicarbonate neutralized acidic tumor extracellular pH [19,20]. In this case, our patient was instructed to follow an alkaline diet and also given supplementary bicarbonate and showed elevation of mean urine pH to 7.0 or higher. Therefore, we speculated that alkalization therapy consisting of both an alkaline diet and bicarbonate may have an alkaline effect to the tumor microenvironment as well as urine pH.

The present case suggested that anti-PD-1 therapy with urine alkalization due to alkalization therapy had potential in obtaining a good anticancer response in EGJ adenocarcinoma. The responses of immunotherapy depend on the immune status of each patient [21]. An acidic tumor microenvironment is reported to be associated with suppression of cancer immunity. Proton–sensing G protein-coupled receptors were identified as pH sensors and they are reported to be activated by acidic extracellular pH and regulate tumor immune responses [22]. In an *in vitro* study, suppressed T-cell response and decreased secretion of IFN- $\gamma$  or TNF- $\alpha$  were observed, and anti-PD-1 therapy with bicarbonate therapy suggested better anticancer effect in mouse models of melanoma [16]. These studies support our case report that nivolumab with an alkalization therapy may improve treatment outcome of EGJ adenocarcinoma.

We acknowledge that our case report has several limitations. First, this study is only a single case report. Therefore, we need more sample cases and a prospective study to validate our result. Second, predictive biomarker for nivolumab such as programmed death-ligand 1 (PD-L1) positivity was not measured. Third, we could not measure the precise extracellular pH of cancer cells, although we showed urine pH elevation. However, measuring the extracellular pH of cancer cells is understandably difficult in the actual clinical setting and clarification of the association between elevation of urine pH and extracellular pH is needed for further investigation.

In conclusion, to the best of our knowledge we demonstrated the relation between good response of nivolumab in an advanced EGJ adenocarcinoma and urine pH elevation after alkalization therapy, which may reflect the alkaline effect against acidic tumor microenvironment.

## 6. Acknowledgements

The authors acknowledge J. Patrick Barron, Professor Emeritus of Tokyo Medical University, for his editing of this manuscript.

## Reference

1. Kawano A, Nakajima TE, Oda I, Hokamura N, Iwasa S, Kato K. Comparison of advanced adenocarcinomas of esophagogastric junction and distal stomach in Japanese patients. *Gastric Cancer*. 2014;17:54-60.
2. Koizumi W, Narahara H, Hara T, Takagane A, Akiya T, Takagi M, et al. S-1 plus cisplatin versus S-1 alone for first-line treatment of advanced gastric cancer (SPIRITS trial): a phase III trial. *Lancet Oncol*. 2008;9:215-21.
3. Yamada Y, Higuchi K, Nishikawa K, Gotoh M, Fuse N, Sugimoto N, et al. Phase III study comparing oxaliplatin plus S-1 with cisplatin plus S-1 in chemotherapy-naive patients with advanced gastric cancer. *Ann Oncol*. 2015;26:141-8.
4. Bang YJ, Van Cutsem E, Feyereislova A, Chung HC, Shen L, Sawaki A, et al. Trastuzumab in combination with chemotherapy versus chemotherapy alone for treatment of HER2-positive advanced gastric or gastro-oesophageal junction cancer (ToGA): a phase 3, open-label, randomised controlled trial. *Lancet*. 2010;376:687-97.
5. Thuss-Patience PC, Kretzschmar A, Bichev D, Deist T, Hinke A, Breithaupt K, et al. Survival advantage for irinotecan versus best supportive care as second-line chemotherapy in gastric cancer--a randomised phase III study of the Arbeitsgemeinschaft Internistische Onkologie (AIO). *Eur J Cancer*. 2011;47:2306-14.
6. Kang JH, Lee SI, Lim DH, Park KW, Oh SY, Kwon HC, et al. Salvage chemotherapy for pretreated gastric cancer: a randomized phase III trial comparing chemotherapy plus best supportive care with best supportive care alone. *J Clin Oncol*. 2012;30:1513-8.
7. Hironaka S, Ueda S, Yasui H, Nishina T, Tsuda M, Tsumura T, et al. Randomized, open-label, phase III study comparing irinotecan with paclitaxel in patients with advanced gastric cancer without severe peritoneal metastasis after failure of prior combination chemotherapy using fluoropyrimidine plus platinum: WJOG 4007 trial. *J Clin Oncol*. 2013;31:4438-44.
8. Wilke H, Muro K, Van Cutsem E, Oh SC, Bodoky G, Shimada Y, et al. Ramucirumab plus paclitaxel versus placebo plus paclitaxel in patients with previously treated advanced gastric or gastro-oesophageal junction adenocarcinoma (RAINBOW): a double-blind, randomised phase 3 trial. *Lancet Oncol*. 2014;15:1224-35.
9. Kang YK, Boku N, Satoh T, Ryu MH, Chao Y, Kato K, et al. Nivolumab in patients with advanced gastric or gastro-oesophageal junction cancer refractory to, or intolerant of, at least two previous chemotherapy regimens (ONO-4538-12, ATTRACTION-2): a randomised, double-blind, placebo-controlled, phase 3 trial. *Lancet*. 2017;390:2461-71.
10. Gatenby RA, Gillies RJ. Why do cancers have high aerobic glycolysis? *Nat Rev Cancer*. 2004;4:891-9.
11. Cairns RA, Harris IS, Mak TW. Regulation of cancer cell metabolism. *Nat Rev Cancer*. 2011;11:85-95.
12. Harguindey S, Orive G, Luis Pedraz J, Paradiso A, Reshkin SJ. The role of pH dynamics and the Na<sup>+</sup>/H<sup>+</sup> antiporter in the etiopathogenesis and treatment of cancer. Two faces of the same coin--one single nature. *Biochim Biophys Acta*. 2005;1756:1-24.
13. Neri D, Supuran CT. Interfering with pH regulation in tumours as a therapeutic strategy. *Nat Rev Drug Discov*. 2011;10:767-77.
14. Robey IF, Baggett BK, Kirkpatrick ND, Roe DJ, Dosesco J, Sloane BE, et al. Bicarbonate increases tumor pH and inhibits spontaneous metastases. *Cancer Res*. 2009;69:2260-8.
15. Robey IF, Lopez AM, Roe DJ. Safety and Tolerability of Long-Term Sodium Bicarbonate Consumption in Cancer Care. *Journal of Integrative Oncology*. 2015;4:128.
16. Pilon-Thomas S, Kodumudi KN, El-Kenawi AE, Russell S, Weber AM, Luddy K, et al. Neutralization of Tumor Acidity Improves Antitumor Responses to Immunotherapy. *Cancer Res*. 2016;76:1381-90.
17. Hamaguchi R, Okamoto T, Sato M, Hasegawa M, Wada H. Effects of an alkaline diet on EGFR-TKI therapy in EGFR mutation-positive NSCLC. *Anticancer Res*. 2017;37:5141-5.
18. Remer T, Manz F. Potential renal acid load of foods and its influence on urine pH. *J Am Diet Assoc*. 1995;95:791-7.
19. Silva AS, Yunes JA, Gillies RJ, Gatenby RA. The potential role of systemic buffers in reducing intratumoral extracellular pH and acid-mediated invasion. *Cancer Res*. 2009;69:2677-84.
20. Martin NK, Robey IF, Gaffney EA, Gillies RJ, Gatenby RA, Maini PK. Predicting the safety and efficacy of buffer therapy to raise tumour pH: an integrative modelling study. *Br J Cancer*. 2012;106:1280-7.
21. Blank CU, Haanen JB, Ribas A, Schumacher TN. CANCER IMMUNOLOGY. The "cancer immunogram". *Science*. 2016;352:658-60.
22. Justus CR, Dong L, Yang LV. Acidic tumor microenvironment and pH-sensing G protein-coupled receptors. *Front Physiol*. 2013;4: 354.