

Seeding the Cancer Cell to the Distant Donor Site of Thigh - A Case Report

Feng GM and Jeng SF*

Department of Plastic Surgery, E-Da Hospital, I-Shou University, Kaohsiung City, Taiwan

Volume 1 Issue 1- 2019

Received Date: 18 Apr 2019

Accepted Date: 15 May 2019

Published Date: 22 May 2019

1. Abstract

The technique and instrument of microsurgery has significantly improved in recent years. Free flap transfers become the popular methods of reconstruction for the head and neck surgery after extirpation of cancer. Immediate reconstruction with two- teams approaches after tumor ablation becomes routine procedure and has allowed the successful rates more than 95% in most of centers. The anterolateral thigh (ALT) flap is widely used in reconstruction because of its minimal donor site morbidity. We report a rare, but possible complication in which tumor seeding was found at the distant donor site of the left thigh after the free ALT transfer. It is not reported in previous articles.

2. Case Report

A 61-year-old male was diagnosed as left buccal cancer (T4N2M0) on June 20, 2002 (**Figure 1**). He received operation of wide excision of tumor ,the tumor was removed with 1cm clear resection margin which resulted in a through and through defect .We reconstructed the defect with a free fibula osteocutaneous flap from left leg for intraoral mucosa and the mandible defect ,and a free ALT flap from right thigh for the cheek defect. The pathology report was well-differentiated squamous cell carcinoma. Ten days later, the ALT flap for cheek defect became failed due to artery insufficiency. Excision of necrotic tissue was performed and reconstructed with an another free ALT flap from his left thigh was done immediately. The donor site of left thigh was closed primarily. Postoperative course was uneventfully. Unfortunately, we found a skin mass 2x2 cm2 in size with ulceration over the previous wound of the donor site of the left thigh three months later after the second operation. The mass (**Figure 2**) was excised with resection margin at least 1 cm under the local anesthesia and the pathology revealed that it was well-differentiated squamous cell carcinoma (**Figure 3**). He received full course of postoperative radiotherapy. No local recurrence for both head and neck, and left thigh was found. The patient was died one and half year later due to sudden onset of cardiac arrest.

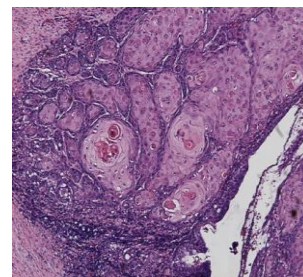


Figure 1: Pathologic result of the original tumor under H-E stain, Squamous cell carcinoma.

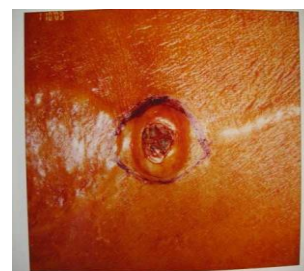

Figure 2: Clinical picture of the skin cancer. The tumor 2x2 cm2 in size was located at the previous wound of ALT flap donor site.

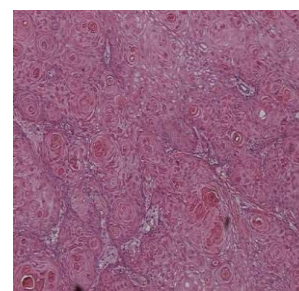


Figure 3: Pathologic finding of the disseminated cancer under H-E stain, Squamous cell carcinoma.

*Corresponding Author (s): Seng-Feng Jeng, Department of Plastic Surgery, E-Da Hospital, No. 1, Yi-Da Road, Jiao-Su Village, Yan-Chao District, Kaohsiung City 824, Taiwan, Tel: +886-7-6150011; Fax: +886-7-6150982; E-mail: jengfamily@hotmail.com

3. Discussion

Immediate reconstruction for the defect caused by extirpation of malignant tumors has become an increasingly important part of modern cancer management [1]. Not only reducing facial deformity and functional impairment consequent to cancer treatment, but also allowed surgical oncologists to treat large tumor successfully. The obvious advantages of immediate reconstruction and strong evidence that it does not increase rate of local tumor recurrence were documented in breast cancer [2-4] as well as the head and neck cancer [5]. Free flap reconstruction can be very useful with a high likelihood of flap survival and wound healing [5]. Some potential complications were encountered as bleeding, dehiscence, tissue necrosis, infection, recurrence, and metastasis [6]. However, the dissemination of the tumor to the donor site is extremely rare [7], especially in distant flap reconstruction. In contrast, the risks and possible mechanisms of the local flap were well documented. The major methods of spread of cancer are by local invasion through contiguity and tissue plane, blood-borne metastasis, lymphatic metastasis, and tumor implantation [6,8]. Local invasion is unlikely because of the tumor being far away from the primary tumor. Blood-borne spread and lymphatic metastasis of tumor from the primary site were thought to be unlikely because of the rarity of spread of squamous cell carcinoma by this routine [8,9]. Cole et al presented that implantation of human cancer cells can occur in one of two possible ways [8]. Iatrogenic implantation has been reported for both benign and malignant tumors, contamination occurring at the time of surgical manipulation [10]. Possible direct contamination during the operative procedure was most likely in this particular patient. Besides these, some articles presented that the surgical stress of immediate reconstruction might weaken host resistance and caused the chance of tumor seeding [6]. The natural killer cell activity, host-tumor interaction, even the compromised nutritional status all play the important roles. The previous reports had no convinced results or discussions about the survival rates of these patients. However, this episode of postoperative complication in free flap transfer has not been reported before. This report emphasizes that tumor implantation at the time of surgery is not only a theoretical complication, but a real potential complication [11]. Precautions should be made throughout of all the procedures to prevent implantation. These include that wounds of recipient site and donor site should be separated away as far as possible. Two separated instruments should be prepared for cancer site and donor site. Surgeons and all the surgical staffs should change their gloves and garments when dealing in more than one surgical field [12].

4. Summary

The advantages of immediate reconstruction with free flap after the head and neck tumor ablation were well known [13-15]. Although the mechanism of tumor seeding is not well established, surgeons should avoid tumor implantation to the donor site as possible by separating recipient site far away from the donor site and two sets of the instruments and operators in two teams. However, if it happened, early diagnosis and aggressive treatments are suggested.

6. Acknowledgements

The authors acknowledge J. Patrick Barron, Professor Emeritus of Tokyo Medical University, for his editing of this manuscript.

Reference

1. Kroll SS, Marchi M. Immediate reconstruction: current status in cancer management. *Tex Med.* 1991; 87(9):67-72.
2. Kroll SS, Ames F, Singletary SE, Schusterman MA. The oncologic risks of skin presentation at mastectomy when combined with immediate reconstruction of the breast. *Surg Gynecol Obstet.* 1991; 172(1): 17-20.
3. Noone RB, Murphy JB, Spear SL, Little JW 3rd. A 6-year experience with immediate reconstruction after mastectomy for cancer. *Plast Reconstr. Surg.* 1985; 76: 258.
4. Noone, RB, Frazier TG, Noone GC. Recurrence of breast carcinoma following immediate reconstruction: a 13-year review. *Plast Reconstr Surg.* 1994; 93(1): 96.
5. Mast BA. Functional outcomes of microsurgical reconstruction of delayed complications following head and neck cancer ablation. *Ann Plast Surg.* 1999; 42(1): 40.
6. Ellison DE, Hoover LA, Ward PH. Tumor Recurrence Within Myocutaneous Flaps. *Ann Otol Rhinol Laryngol.* 1987; 96: 26-8.
7. Kroll SS, Tavollali M, Castello-Sendra J, Pollock RE. Risk of Dissemination of Cancer to Flap Donor Sites During Immediate Reconstructive Surgery. *Ann Plast Surg.* 1994; 33: 573.
8. Cole WH. The Mechanisms of Spread of Cancer. *Surg Gynecol Obstet.* 1973; 137: 853.
9. Mahaffey PJ, Sommerlad BC. Tumor Spread in a Delto-pectoral Pedicle Flap Used in Reconstruction. *Br J Plast Surg.* 1985; 38(1): 43-5.
10. Richard JC, and Gilbert PM. Tumor Implantation to a Temporalis Muscle Flap Donor Site. *Br J Oral Max. Surg.* 1986; 24: 102.
11. Jeffrey TS. Tumor Implantation in a Skin Flap. *JAMA.* 1983; 250: 2670.

12. Robbins KT, Gayle EW. Chest Wall Metastasis as a Complication of Myocutaneous Flap Reconstruction. *J Otolaryn.* 1984; 13: 13.
13. Jeng SF, Kuo YR, Wei FC, Su CY, Chien CY. Reconstruction of Extensive Composite Mandibular Defects with Large Lip Involvement by Using Double Free Flaps and Fascia Lata Grafts for Oral Sphincters. *Plast Reconstr Surg.* 2005; 115(7):1830.
14. Jeng SF, Kuo YR, Wei FC, Su CY, Chien CY. Reconstruction of Concomitant Lip and Cheek Through-and-Through Defects with Combined Free Flap and an Advancement Flap from the Remaining Lip. *Plast. Reconstr. Surg.* 2004; 113(2):491.
15. Kuo YR, Seng-Feng J, Kuo FM, Liu YT, Lai PW. Versatility of the Free Anterolateral Thigh Flap for Reconstruction of Soft-Tissue Defects: Review of 140 Cases. *Ann Plast Surg.* 2002; 48(2):161.