

Bevacizumab Induced Thrombotic Microangiopathy in a 71-Year Old Glioblastoma Patient

Mathieu Chevallier^{1*}, Francois Girardin², Nicolas Mirlesse³ and Thibaud Koessler¹

¹Department of Oncology, Geneva University Hospital, Geneva, Switzerland

²Division of Clinical Pharmacology and Toxicology, Department of Anaesthesiology, Clinical Pharmacology, Intensive Care and Emergency Medicine, Geneva University Hospital, Geneva, Switzerland

³Department of Internal Medicine, Geneva University Hospital, Geneva, Switzerland

Volume 3 Issue 1- 2020

Received Date: 16 June 2020

Accepted Date: 29 June 2020

Published Date: 03 July 2020

1. Introduction

Bevacizumab is a humanized monoclonal antibody which primarily targets Vascular Endothelial Growth Factor (VEGF). Renal injury, including proteinuria and nephrotic syndrome, is a common adverse event associated with anti-VEGF therapy [1]. It has been described in patients treated for renal cell carcinoma, ovarian, breast, colon, and lung cancers [2].

2. Keywords

Lomustine; Hemolytic anemia; Bevacizumab Thrombotic microangiopathy; Drug-induced thrombotic microangiopathy

Thrombotic Microangiopathy (TMA) is a syndrome that includes hemolytic anemia and thrombocytopenia with organ damage. Kidney biopsies show typical endothelial injury with presence of fibrin microthrombus in glomeruli with mucoid changes and typical “onion skin lesions” of renal arterioles [3].

To our knowledge, we report the first case described in a glioblastoma patient and discuss the occurrence of severe but reversible thrombotic microangiopathy associated with bevacizumab.

3. Case Report

3.1. Diagnosis

In October 2017, a 71-year old male was diagnosed with right parietal glioblastoma, with wild-type Isocitrate Dehydrogenase (IDH) and methylated O-methylguanine-DNA Methyltransferase (MGMT). He was known for stage I hypertension treated with amlodipine and normocytic normochromic anemia.

3.2. Treatment

The patient had a subtotal resection of a glioblastoma in October 2017, followed by the standard adjuvant treatment based on the Stupp protocol, with temozolomide 75 mg/m² per day with concomitant radiotherapy (60 Gy) from November 2017 to January 2018, followed by temozolomide 200 mg/m² per day on days 1 to 5 of every four-week cycle [4].

After four months, adjuvant chemotherapy was stopped due to radiological and clinical progression (left hand dysesthesia and partial epileptic seizures).

The patient started lomustine (100 mg/m² on day 1 of the 6-week cycle) and bevacizumab (10 mg/kg every 2 weeks) in June 2018 [5]. An antiepileptic therapy with lacosamide was also introduced. The patient experienced clinical improvement and radiological stability. Lomustine was reduced to 75% then 50% due to grade

2 [6] thrombocytopenia (nadir 69 G/l), and was stopped after the usual six cycles, in January 2019. Bevacizumab was continued as monotherapy. The platelet count normalized after the decrease in lomustine dosage.

3.3. Evolution

After a few weeks, thrombocytopenia reappeared (91 G/l, grade 1) and anemia (110 to 100 g/l) worsened. Fragments were present in the blood smear (Figure 1), with a negative Coombs test. Hemolysis was suspected, given low haptoglobin (<81 mg/l) and high lactate dehydrogenase (334 U/l) values. The patient developed concurrent hypertension and non-nephrotic range proteinuria (3 g/24h), without functional kidney failure (stable values of serum creatinine (90 to 120 umol/l) and eGFR CDK-EPI (50 to 60 ml/min/1.73m²)), suggesting renal damage. The patient remained asymptomatic and did not present purpura. No neurological symptoms were noted (eg seizures, headache, confusion, focal deficit). The patient declined renal biopsy. However, in spite of antihypertensive drugs (enalapril 10 mg/d and amlodipine 20 mg/d), blood pressure remained high (>160/95 mmHg). The clinical constellation strongly suggested an iatrogenic TMA.

3.4. Discontinuation of Bevacizumab

Given radiological and clinical stability, bevacizumab was discontinued in March 2019. Thrombocytopenia, proteinuria and hyper-

*Corresponding Author (s): Mathieu Chevallier, Oncology Department, Geneva University Hospital, 4 rue Gabrielle Perret Gentil, 1205, Geneva, Switzerland, Tel: 022 372 4295; Fax: 022 372 9858; E-mail: mtcv@hcuge.ch

Citation: Chevallier M, Bevacizumab Induced Thrombotic Microangiopathy in a 71-Year Old Glioblastoma Patient. Clinics of Oncology. 2020; 3(1):1-3.

tension spontaneously vanished within four weeks. Follow up after one year showed no sign of progression of the latest MRI (May 2020) and stable laboratory values.

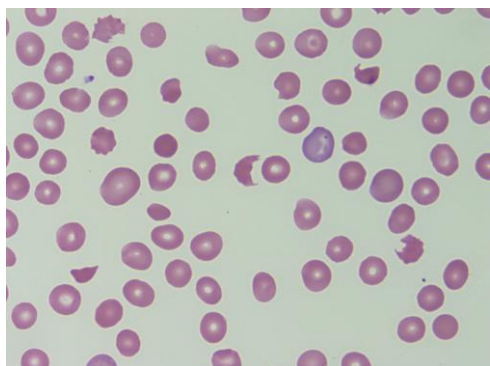


Figure 1: Typical fragments (schistocytes)

4. Discussion

Two typical phenotypes of TMA are thrombotic thrombocytopenic purpura (TTP, Moschcowitz syndrome) and hemolytic uremic syndrome (HUS, Gasser syndrome). The etiology might be either acquired or innate, with an annual incidence of about 4 per 1'000'000 individuals. The acquired forms may be due to a deficiency in ADAMTS13 protein, Shiga toxin, complement-mediated, or drugs either by an immune reaction or polymorphic toxic effects that are dose-dependent [7].

Based on the international pharmacovigilance survey and literature review on drug-induced TMA, we identified 586 patients within 344 articles. There was sufficient evidence to establish high level of imputability for 22 drugs and toxic substances, of which three cases involved bevacizumab [8]. According to the WHO database (cases spontaneously reported to the pharmacovigilance authorities in several countries, without specifying causality or incidence), among 60 763 adverse reactions to bevacizumab, there are 119 cases of thrombotic microangiopathy, 23 cases of microangiopathic hemolytic anemia, nine cases of thrombocytopenic thrombotic purpura [9].

Bevacizumab is a recombinant humanized monoclonal antibody (Ig G1/kappa), an inhibitor of VEGF growth factor binding to its Flt-1 (VEGFR-1) and KDR (VEGFR-2) receptors located on the surface of endothelial cells. Neutralization of VEGF biological activity reduces tumor vascularization, resulting in inhibition of tumor growth. It is indicated for the treatment of multiple cancers both as monotherapy, i.e., in recurrent glioblastoma after temozolomide, or in combined chemotherapy, e.g. in metastatic colorectal, breast or ovarian carcinoma.

The main adverse events attributed to bevacizumab in clinical studies were hypertension, proteinuria, as well as acute and chronic kidney injury. Hypertension and proteinuria are dose-dependent and are described as mild to moderate and controllable [10, 11].

Bevacizumab, as well as other anti-VEGF agents [12], are respon-

sible for both variants of TMA, based on renal involvement and, if available, confirmed by biopsy results. Underlying pharmacological mechanisms could be diverse: immune (dose-independent adverse effect) or caused by direct toxicity, depending on drug dose and exposure [13, 14]. TAM is an adverse drug reaction that could appear regardless of the treatment duration [13]. Whilst the incidence is really determined, several cases of TMA in patients taking bevacizumab have been described in the literature [14, 15]. Pre-existing hypertension is a risk factor [13].

The decision to discontinue treatment depends on the severity of the adverse events, i.e., organ damage and thrombopenia. Current guidelines suggest supportive care with drug discontinuation and introduction of anti-hypertensive therapy. In our hypothesis of a dose-dependent toxicity, some authors suggest possible re-introduction with dose-reduced regimen, although clinical evidence is lacking [13, 14]. In this case, due to the stability of the glioblastoma, we stopped bevacizumab and monitored the patient clinically and radiologically.

5. Conclusion

Drug-mediated TMA could be toxic dose-related reactions without immune reactions. Blood lineage drop combined with heterogeneous organ failure should rise the suspicion of TMA: blood smear in search of schizocytes could guide diagnosis and identify TMA variants to stop or taper imputable medication. Based on biological and clinical evidence in the glioblastoma patient, we concluded that bevacizumab was responsible of a TMA variant without purpura, which was reversible after drug cessation (positive dechallenge). The chronology of the clinical presentation and improvement after discontinuation strongly supports the hypothesis that the therapeutic agent was the causal factor, which triggered the TMA variant without purpura and neurological signs. The putative mechanism likely stems from the VEGF inhibition with a gradual onset of renal failure that occurred over weeks or months.

References

1. Person F, et al. Bevacizumab-associated glomerular microangiopathy. *Mod. Pathol.* 2019; 32: 684-700.
2. Izzedine H, et al. Kidney diseases associated with anti-vascular endothelial growth factor (VEGF): An 8-year observational study at a single center. *Med. (United States)*. 2014; 93: 333-9.
3. Yu XJ, et al. Clinical and renal biopsy findings predicting outcome in renal thrombotic microangiopathy: A large cohort study from a single institute in China. *Sci. World J.* 2014; 2014.
4. Stupp, R. et al. Radiotherapy plus Concomitant and Adjuvant Temozolomide for Glioblastoma. *N. Engl. J. Med.* 2005; 352; 987-96.
5. Wick W, et al. Lomustine and bevacizumab in progressive glioblastoma. *N. Engl. J. Med.* 2017; 377: 1954-63.
6. Cancer Therapy Evaluation Program (CTEP). Common Terminology

- gy Criteria for Adverse Events (CTCAE). *Cancer Ther. Eval. Progr.* 2017; 5: 155.
7. George JN, Nester CM. Syndromes of thrombotic microangiopathy. *N. Engl J Med.* 2014; 371: 654-66.
 8. Al-Nouri ZL, Reese JA, Terrell DR, Vesely SK, George JN. Drug-induced thrombotic microangiopathy: A systematic review of published reports. *Blood.* 2015; 125:616-8.
 9. Vigiaccess. Vigiaccess Online. <http://www.vigiaccess.org/> (2019). Accessed 20 Sept 2019
 10. Swissmedic. Swissmedicinfo. <https://www.swissmedicinfo.ch/> (2019). Accessed 20 Sept 2019
 11. Aronson, J. K. *Meyler's Side Effects of Drugs.* (2015).
 12. Izzedine H, Perazella MA. Thrombotic Microangiopathy, Cancer, and Cancer Drugs. *Am. J. Kidney Dis.* 2015; 66: 857-68.
 13. Kheder El-Fekih R, Deltombe C, Izzedine H. Thrombotic microangiopathy and cancer. *Néphrologie & Thérapeutique.* 2017; 13: 439-47.
 14. Bektas M, Samancı NS, Cokgezer S, Keskin D, Demirelli FH. A severe case of bevacizumab-induced thrombotic microangiopathy. *J. Oncol. Pharm. Pract.* 2019; 25:1754-7.
 15. Taro H, Osamu I, Yoshiko S, Yoshio T. Renal thrombotic microangiopathy caused by bevacizumab. *Nephrology.* 2018; 23: 378-9.